

# External Ophthalmomyiasis by *Oestrus Ovis*: Two Case Reports from Nepal

Nabina Maharjan,<sup>a,d</sup> Ashish Jamarkattel,<sup>b,d</sup> Bhagavat Prasad Nepal<sup>c,d</sup>

## ABSTRACT

**Introduction:** Ophthalmomyiasis is an infestation of eye with larvae of dipteran flies most commonly by *Oestrus ovis* (Sheep nasal botfly). External ophthalmomyiasis in humans is a rare condition seen in people residing in rural areas and also living close to livestock. **Case Report:** We report two cases of external ophthalmomyiasis in 22 years old male and 38 years old female both having history of sudden onset of foreign body sensation and redness in left and right eyes respectively. **Conclusion:** This external ophthalmomyiasis presenting nonspecific symptoms similar to acute conjunctivitis is the first case reported in Nepal to the best of our knowledge. This report may aware all ophthalmologists about larval conjunctivitis preventing misdiagnosis.

**Keywords:** Conjunctivitis; Nepal; Ophthalmomyiasis; *Oestrus ovis*

## INTRODUCTION:

Myiasis is an infestation of larval stage of dipteran flies in animals or humans.[1] The common sites are skin wounds, however nose, nasal sinuses, throat, eyes and urogenital tract are also infested.[2] *Oestrus ovis* is an obligate parasite in nasal cavities of sheep and goat, whereas humans are accidental hosts.[3]

*Oestrus ovis* belong to Class Insecta, Order Diptera and Family Oestridae.[4] The adult fly looks like honey bee having yellow to grey brown color, 10-12 mm length.[3] This viviparous adult fly deposit newly hatched first stage larvae in nostril, conjunctiva and mouth of usual host like sheep, goat and horse.[5] This larva transforms from first stage larvae to third stage larvae in host and this

third mature larvae get expelled down in ground and pupate in soil and adult fly emerge after 3-4 weeks that live for a month. In accidental host that is in human first stage larvae is incapable of developing beyond first stage and larva can live only for 10 days but within this period it can penetrate the sclera and reach the vitreous and retina causing severe panuveitis or endophthalmitis.[6]

Ophthalmomyiasis occurs in three forms namely external, internal and orbital. External ophthalmomyiasis refers to infestation of the lids or conjunctivae, whereas internal ophthalmomyiasis refers to intraocular infestation. Orbital myiasis can also occur but is very rare.[7] External ophthalmomyiasis in humans is rare cosmopolitan disorder, mainly those residing in rural areas living close to livestock areas.[5] To the best of our knowledge no case reports have been published regarding *Oestrus ovis* in Nepal. We report here two cases of external ophthalmomyiasis in Out Patient Department of Ophthalmology at Lumbini Medical College and Teaching Hospital, Palpa.

**Submitted:** 16 October, 2020

**Accepted:** 15 March, 2021

**Published:** 24 March, 2021

a- Lecturer, Department of Microbiology

b- Resident, Department of Ophthalmology

c- Professor, Department of Ophthalmology,

d- Lumbini Medical College and Teaching Hospital, Palpa, Nepal.

## Corresponding Author:

Nabina Maharjan

e-mail: [nabinamaharjan75@gmail.com](mailto:nabinamaharjan75@gmail.com)

ORCID: <https://orcid.org/0000-0003-1873-4646>

## How to cite this article:

Maharjan N, Jamarkattel A, Nepal BP. External Ophthalmomyiasis by *Oestrus Ovis*: Two Case Reports from Nepal. *Journal of Lumbini Medical College*. 2021;9(1):4 pages. DOI: <https://doi.org/10.22502/jlmc.v9i1.407>. Epub: 2021 March 24.



Licensed under CC BY 4.0 International License which permits use, distribution and reproduction in any medium, provided the original work is properly cited.

## CASE REPORT:

### Case 1

A 22-year-old male presented to the outpatient clinic of ophthalmology with a chief complaint of sudden onset of foreign body sensation with associated redness, watering and intolerance to light in the left eye for one day. He tried splashing his eye with plain water frequently for symptomatic relief but to no avail. He had no history of trauma, other ocular and systemic illness.

On examination, his visual acuity of both eyes were 6/6. Both eyelids of left eye were mildly edematous. Conjunctiva was diffusely congested with profuse watering. There were no follicles, discharge and pre-auricular lymphadenopathy. Extraocular muscle movement was full. Slit lamp examination revealed multiple tiny whitish 1.5 to 2 mm larva in lower forniceal conjunctiva initially. Few were actively mobile wriggling on bulbar and forniceal conjunctiva and few were attached to conjunctiva by its black head. After application of 4% lignocaine drop 25 larvae were taken out and were sent to microbiology department in normal saline for identification. Posterior segment evaluation was done by 90 Dioptre lens in slit-lamp biomicroscope after dilatation of pupil by tropicamide 1%. Fundus examination findings revealed no abnormality. Right eye examination was normal. Macroscopic examination revealed larva which measured 1.5 to 2 mm in length and had white slender body with black colored heads (Fig. 1). Microscopically, it had 11 segments (metamers), each segment with two to three rows of spines (Fig. 2A). The cephalic end

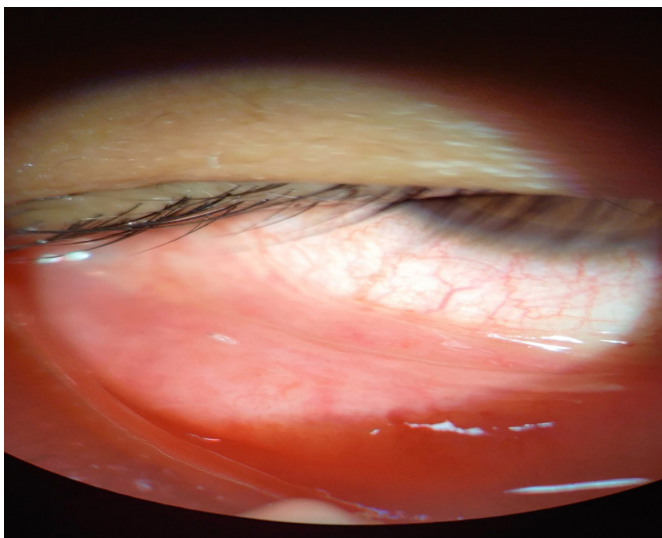


Fig 1: White translucent larva of *Oestrus ovis* on conjunctiva.

had two large buccal hooks and caudal end had two tubercle each containing ten curved spines (Figs. 2B and C). The patient was prescribed with ofloxacin and ketorolac eye drops to be applied to the affected eye four times daily. The patient's signs and symptoms were markedly improved and no other larva were identified on further detailed examination in the follow up next day.

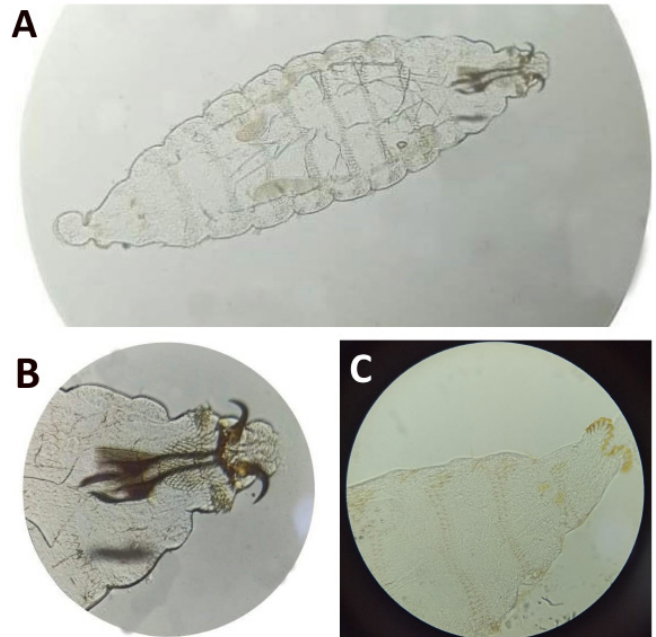


Fig 2: A- Larva of *Oestrus ovis* larva (x 100). B-Cephalic portion of *Oestrusnovis* larva (x400) showing two black buccal hooks. C-Posterior end of the larvae (X400) showing two tubercles and many curved spines.

### Case 2

A 38-year-old female, presented to outpatient department of ophthalmology with history of sudden onset of foreign body sensation, redness, swelling of her eyelids of right eye for three days following insect sting while cutting grass at her field. Her husband noticed mobile worms in her right eye and removed five worms at home but her symptoms were unalleviated. She had no other known ocular and systemic illness in the past.

On examination, her visual acuity of both eyes was 6/6. Both eyelids of right eye were mildly edematous. Conjunctiva was diffusely congested and profuse watering. There were no follicles, discharge and pre-auricular lymphadenopathy. Extraocular muscle movement was full. Slit lamp examination revealed multiple tiny whitish larvae in lower bulbar and forniceal conjunctiva. Few were actively mobile and few were attached to conjunctiva by its black

head. After application of 4% lignocaine drop nine larvae were taken out and were sent to microbiology department in normal saline for identification. Posterior segment evaluation was done by 90 Dioptre lens in slit-lamp biomicroscope after dilatation of pupil by tropicamide 1%. Fundus examination revealed no abnormality. Examination of the left eye was normal. The patient was too prescribed with ofloxacin and ketorolac similar to the first case who showed improvement at next day follow up.

## DISCUSSION:

We described herein two first reported cases of human external ophthalmomyiasis caused by *Oestrus ovis* (sheep nasal botfly) in Nepal. Based upon the morphological description the larvae were at the first stage of development in the present case. [2,5,8]

The viviparous sheep botfly deposits larva in human eyes accidentally while flying. Mostly larva is presented in external ocular surface where it holds in conjunctiva by its pointed hooks. This causes development of symptoms similar to acute conjunctivitis with itching, foreign body sensation and watering.[9]

Timely removal of all larvae from eye is the first step in treatment of external ophthalmomyiasis. Irrigation of eye is not useful to remove larvae as it holds tightly to the conjunctival surface with its hooks. So they should be removed with the help of cotton swab and forceps on local anesthesia carefully. [8] In order to provide relief from symptoms and to prevent secondary infection, topical antibiotics along with anti-inflammatory drugs are prescribed. Follow-up examination was recommended to avoid post treatment complications or recurrence.[3] *Oestrus ovis* are not able to produce proteolytic enzymes so are unable to penetrate cornea or sclera.[9] However, external ophthalmomyiasis requires prompt management as it may lead to serious complications like corneal ulcer, decreased vision and invasion into eye globe causing endophthalmitis, iridocyclitis and even blindness.[2,9] These complicated conditions were not seen in our case as timely removal of larvae with proper treatment was provided promptly.

Both patients in the present study belonged to rural area, involved in agricultural activities and had a history of close contact with livestock. Most of the other case studies also showed greater frequency

of ophthalmomyiasis among farmers and shepherds. [2] The patient in the first case had domesticated three buffaloes and three goats at his home, and was in close contact with them daily. The patient in the second case too had one buffalo, three cows and six goats at her home.

*Oestrus ovis* has three annual peaks in spring, summer and autumn.[5] In our study also the first case presented to us in May and the second case in August. Many previous papers have also reported most of the external ophthalmomyiasis cases in spring and summer seasons.[2]

## CONCLUSION:

External ophthalmomyiasis by *Oestrus ovis* are first reported cases in Nepal. It is one of the differential diagnosis of conjunctivitis especially in rural area where people live very close contact with their livestock. Misdiagnosis and delay in treatment may lead to many severe complications. All ophthalmologists should be very aware about this external ophthalmomyiasis to prevent its complications.

**Conflict of Interest:** The authors declare that no competing interests exist.

**Financial disclosure:** No funds were available.

## REFERENCES:

1. Atreya A, Nepal S, Bhattarai A, Kanchan T. Obligate Myiasis: A Case Series From Nepal. Kathmandu Univ Med J (KUMJ). 2018;16(63):269-71. PMID: [31719320](https://pubmed.ncbi.nlm.nih.gov/31719320/).
2. Pandey A, Madan M, Asthana AK, Das A, Kumar S, Jain K. External ophthalmomyiasis caused by *Oestrus ovis*: a rare case report from India. Korean J Parasitol. 2009;47(1):57-9. PMID: 19290093. DOI: <https://doi.org/10.3347/kjp.2009.47.1.57>
3. Abdellatif MZ, Elmazar HM, Essa AB. *Oestrus ovis* as a Cause of Red Eye in Aljabal Algharbi, Libya. Middle East Afr J Ophthalmol. 2011;18(4):305-8. PMID: [22224020](https://pubmed.ncbi.nlm.nih.gov/22224020/). DOI: <https://doi.org/10.4103/0974-9233.90133>
4. Zhang A, Nie Q, Song J. External ophthalmomyiasis caused by *Oestrus ovis* in east China. Trop Doct. 2018;48(2):169-171. PMID: [29111870](https://pubmed.ncbi.nlm.nih.gov/29111870/). DOI: <https://doi.org/10.1177/0049475517737456>
5. Basmacıyan L, Gabrielle PH, Valot S, Sautour M, Buisson JC, Creuzot-Garcher C, et al. *Oestrus ovis* external ophtalmomyiasis: a case report in Burgundy France. BMC Ophthalmol. 2018;18(1):335. PMID: [30577838](https://pubmed.ncbi.nlm.nih.gov/30577838/). DOI: <https://doi.org/10.1186/s12886-018-1003-z>
6. Akdemir MO, Ozen S. External ophthalmomyiasis caused by *Oestrus ovis* misdiagnosed as bacterial conjunctivitis. Trop Doct. 2013;43(3):120-3. PMID: [23780871](https://pubmed.ncbi.nlm.nih.gov/23780871/). DOI: <https://doi.org/10.1177/0049475513492153>
7. Albert DM, Miller J. Albert and Jakobiec's Principles and Practice of Ophthalmology. 3<sup>rd</sup> ed. (4 volume set). Elsevier Inc; 2013. Indian Reprint ISBN: 978-81-312-3542-3.
8. Rao S, Radhakrishnasetty N, Chadalavada H, Hiremath C. External ophthalmomyiasis by *Oestrus ovis*: A case report from Davangere. J Lab Physicians. 2018;10(1):116-117. PMID: [29403219](https://pubmed.ncbi.nlm.nih.gov/29403219/). DOI: [https://doi.org/10.4103/jlp.jlp\\_18\\_17](https://doi.org/10.4103/jlp.jlp_18_17)
9. Dutta Majumder P, Jeswani P, Jeyathilakan N, Biswas J. External ophthalmomyiasis due to *Oestrus ovis*. Indian J Ophthalmol. 2019;67(3):404-5. PMID: [30777968](https://pubmed.ncbi.nlm.nih.gov/30777968/). DOI: [https://doi.org/10.4103/ijo.ijo\\_1391\\_18](https://doi.org/10.4103/ijo.ijo_1391_18)