https://doi.org/10.22502/jlmc.v12i2.572

Case Report

Bayonet Apposition of Distal Radius and Ulna Fracture Managed Conservatively with Cast: A Case Report

Prabin GC,*[,1] Bishal Kafle,[1] Manish Shrestha,[1] Irfan Razi[1]

ABSTRACT:

The management of completely displaced distal radius and ulna fractures with bayonet apposition in children remains controversial. While many authors recommend reduction with or without Kirschner wire fixation to prevent redisplacement, recent studies suggest favorable outcomes with conservative treatment due to the excellent remodeling potential of the distal radius. We report the case of a five-year-old child with a completely displaced distal radius and ulna fracture with bayonet apposition. Operative management was initially planned; however, surgery was deferred as the child was unfit for anesthesia due to a persistent cough. The fracture was managed with cast immobilization after correction of the visible deformity without anatomical reduction. Serial follow-up radiographs demonstrated progressive remodeling and satisfactory fracture union. At final follow-up at three months, the child had full, painless wrist function with no clinical deformity.

Keywords: Bayonet apposition; Cast immobilization; Conservative management; Pediatric distal radius and ulna fracture; Remodeling.

INTRODUCTION:

Distal radius and ulna fractures are among the most common fractures in children. It accounts for up to about 20% of all childhood fractures. Undisplaced fractures can be managed conservatively with a cast. Similarly, displaced fractures can also be treated conservatively with closed reduction and a cast, but the main challenge and concern is to maintain the fracture alignment.[1] Some authors suggest that displaced fractures can be managed with reduction and cast application, whereas others recommend pinning to prevent redisplacement.[2-4]

Submitted*: 11 October 2024*
Accepted*: 13 December 2024*
Published*: 30 December 2024*

1 - Department of Orthopedics, Lumbini Medical College – Teaching Hospital, Palpa, Nepal

Corresponding Author:
Prabin GC
e-mail: praveenchetrri@gmail.com
ORCID: https://orcid.org/0009-0002-2291-4885

How to cite this article:
GC P, Kafle B, Shrestha M, Razi I. Bayonet Apposition of Distal Radius and Ulna Fracture Managed Conservatively with Cast: A Case Report. J Lumbini Med Coll. 2024;12(2):21-23 DOI: 10.22502/jlmc.v12i2.572.

However, some other authors in their articles, concluded that no reduction is required for displaced distal radius and ulna fractures in children, as these fractures have excellent remodeling potential and can heal with acceptable outcomes.[5-7]

Inspired by these studies, we report a case of displaced distal radius and ulna fracture with an overriding (bayonet) position managed successfully conservatively; only the visible deformity was reduced while applying the cast.

CASE REPORT:

A five-year-old female child presented to the emergency department with pain and swelling over the right wrist following a fall from a staircase. The child sustained a direct impact injury to the right wrist. Clinical examination revealed a tender swelling with gross deformity around the right wrist. There was no open injury, and neurovascular examination was normal. The movement at the wrist was restricted due to pain.

Radiographs of the right wrist and forearm were sent, which showed a fracture of the distal radius and ulna with displacement and bayonet apposition in anteroposterior (AP) and lateral views (**Fig. 1**).

Initially, operative management was planned. But the child had an associated cough

Licensed under CC BY 4.0 *International License which permits use, distribution and reproduction in any medium, provided the original work is properly cited.*



***Fig 1**. Initial post-trauma radiograph*

and was not fit for anesthesia, so above elbow slab was applied, and the child was advised to follow up after one week. At the one-week follow-up, the child still had a cough and was not fit for anesthesia again. So, considering the patient's age and good remodeling potential, and after discussion with the parents regarding treatment options, risks, and benefits, conservative management was considered an appropriate treatment option and an above-elbow cast was applied (**Fig. 2**).



***Fig 2**. Post-cast radiograph*

Serial follow-up was done to monitor displacement and fracture union. At three months follow-up, radiographs showed good union with proper alignment (**Fig. 3**). Clinically, the patient had good wrist function with a satisfactory range of motion and no significant symptoms.

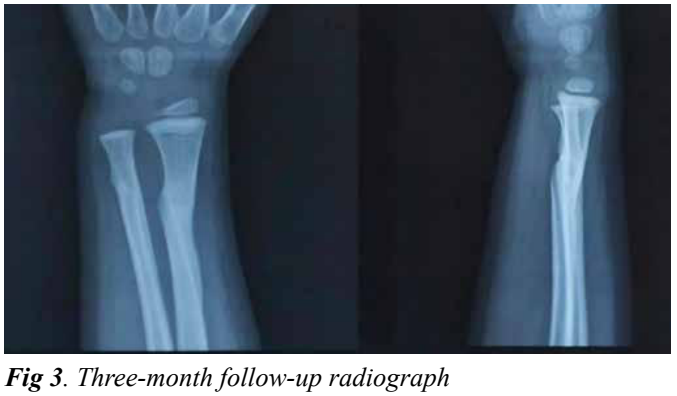

***Fig 3**. Three-month follow-up radiograph*

DISCUSSION:

Distal radius and ulna fractures are the most common fractures in children. Undisplaced fractures are usually managed with cast immobilization because the distal radial metaphysis has excellent remodeling potential due to its proximity to the growth plate.[1] According to Wilkins, they can remodel angulation of up to 30–35° in the sagittal plane and 10° in the coronal plane in children with at least five years of growth remaining. Bayonet apposition of up to one cm may also remodel in children up to 12 years of age when overall alignment is acceptable.[8]

The management of completely displaced distal radial metaphyseal fractures remains controversial. Do et al. reported that many of these fractures do not require primary reduction because of their high remodeling potential.[6] Similarly, Martinelli et al. demonstrated that children aged less than eight years with overriding distal radius fractures achieved excellent clinical and radiographic outcomes with long-arm cast immobilization without reduction.[7] Crawford et al. concluded that overriding distal radial metaphyseal fractures in children aged less than 10 years can be successfully treated with cast immobilization without fracture reduction. This method provides excellent clinical and radiographic outcomes while reducing treatment cost, time, and the need for sedation or surgery.[5]

In contrast, several authors recommend reduction and stabilization for completely displaced fractures. McLauchlan et al. reported that percutaneous K-wire fixation is a safe and reliable method for maintaining fracture alignment in completely displaced distal radial metaphyseal fractures.[3] Likewise, Zamzam and Khoshhal recommended closed reduction under general anesthesia followed by percutaneous K-wire fixation to maintain stability and prevent redisplacement, even after satisfactory reduction.[4] Wendling-Keim et al. also recommended closed reduction and casting as the treatment of choice for displaced distal radius fractures in children, with primary Kirschner wire fixation for fractures with residual displacement or a high risk of redisplacement.[2]

Thus, there are two accepted treatment approaches for displaced distal radius fractures. One favors reduction with or without K-wire fixation to achieve and maintain anatomical alignment, while the other supports conservative treatment even without reduction in younger children because of their excellent remodeling potential. In our case, operative management was initially planned because

of complete displacement with bayonet apposition. The child was not fit for general anesthesia due to a persistent cough, so conservative treatment with cast immobilization was chosen. Serial follow-up radiographs showed progressive remodeling and satisfactory fracture union. At final follow-up, the child had full wrist function without pain, deformity, or functional limitation. Our findings are consistent with those reported by Do et al., Martinelli et al., and Crawford et al., demonstrating that excellent radiographic and functional outcomes can be achieved in selected young children without anatomical reduction.

Careful patient selection remains essential when considering conservative treatment without anatomical reduction. Factors favoring this approach include young age with substantial remaining growth, a metaphyseal fracture location, absence of neurovascular injury or open fracture, acceptable overall alignment, reliable parental compliance, and the ability to attend regular clinical and radiographic follow-up. Older patients who have limited remodeling potential, unstable fracture patterns, associated injuries, or are unlikely to come for regular follow-up may be better managed with reduction and stabilization. This case adds to the growing evidence that completely displaced distal radial metaphyseal fractures with bayonet apposition can heal successfully with cast immobilization alone in carefully selected young children. However, as this is a single case report, the findings should be interpreted with caution and cannot be generalized to all patients. Larger prospective studies are needed to better define the indications for conservative management without anatomical reduction.

CONCLUSION:

The optimal management of completely displaced distal radial metaphyseal fractures with bayonet apposition in children remains a matter of debate. Although reduction with or without K-wire fixation is widely recommended to maintain alignment and prevent redisplacement, this case demonstrates that excellent fracture union, remodeling, and functional recovery can be achieved with cast immobilization alone in a young child with significant remodeling potential. Our findings support the growing evidence that anatomical reduction may not be necessary, especially in young children with significant amount of growth remaining. However, conservative management should be undertaken with appropriate parental counseling and close clinical and radiographic follow-up to ensure satisfactory healing.

Consent:

Informed consent was obtained from the patient's parents for publication of this case report and accompanying images.

Conflict of Interest: None

Source of Funding: None.

REFERENCES

1. Akar D, Köroğlu C, Erkus S, Turgut A, Kalenderer Ö. Conservative follow-up of severely displaced distal radial metaphyseal fractures in children. Cureus. 2018;10(9):e3259. PMID: 30430048 DOI: 10.7759/cureus.3259
2. Wendling-Keim DS, Wieser B, Dietz HG. Closed reduction and immobilization of displaced distal radial fractures. Method of choice for the treatment of children? Eur J Trauma Emerg Surg. 2015;41(4):421-8. PMID: 26038007 DOI: 10.1007/s00068-014-0483-7
3. McLauchlan GJ, Cowan B, Annan IH, Robb JE. Management of completely displaced metaphyseal fractures of the distal radius in children. A prospective, randomised controlled trial. J Bone Joint Surg Br. 2002;84(3):413-7. PMID: 12002503 DOI: 10.1302/0301-620x.84b3.11432
4. Zamzam MM, Khoshhal KI. Displaced fracture of the distal radius in children: factors responsible for redisplacement after closed reduction. J Bone Joint Surg Br. 2005;87(6):841-3. PMID: 15911670 DOI: 10.1302/0301-620x.87b6.15648
5. Crawford SN, Lee LS, Izuka BH. Closed treatment of overriding distal radial fractures without reduction in children. J Bone Joint Surg Am. 2012 Feb 1;94(3):246-52. PMID: 22298057 DOI: 10.2106/jbjs.k.00163
6. Do TT, Strub WM, Foad SL, Mehlman CT, Crawford AH. Reduction versus remodeling in pediatric distal forearm fractures: a preliminary cost analysis. J Pediatr Orthop B. 2003;12(2):109-15. PMID: 12584495 DOI: 10.1097/01.bpb.0000043725.21564.7b
7. Marinelli M, Massetti D, Facco G, Falcioni D, Coppa V, Maestri V, et al. Remodeling of distal radius fractures in children: preliminary retrospective cost/analysis in level II pediatric trauma center. Acta Biomed. 2021;92(5):e2021390. PMID: 34738560 DOI: 10.23750/abm.v92i5.11971
8. Wilkins KE. Principles of fracture remodeling in children. Injury. 2005;36 (Suppl):A3-11. PMID: 15652934 DOI: 10.1016/j.injury.2004.12.007